

Available online at www.sciencerepository.org

Science Repository



Case Report

Repair of Complicated Multiple Incisional Hernia on One Patient: Erlangen Inlay-Onlay Mesh Repair Combined with Extended Spider-Suture Technique

Resit Demir^{1,2*}

¹Medical Care Center, MVZ PD Dr. Demir & Colleagues, Nürnberg, Germany

²Department of Surgery, Friedrich-Alexander University Hospital Erlangen-Nürnberg, Nürnberg, Germany

ARTICLE INFO

Article history:

Received: 16 October, 2020

Accepted: 28 October, 2020

Published: 4 November, 2020

Keywords:

Abdominal incisional hernia

open mesh repair

sublay technique

spider suture

fascia suture

ABSTRACT

Purpose: Surgical treatment of large ventral hernia after laparotomy is a challenge for surgeons. It becomes even more complicated if there is more than one hernia on the abdominal wall and patients have additional risk factors such as BMI > 30, severe CAD or lung problems. In the following work I would like to introduce you two patients who had exactly these constellations and who could be operated successfully by combining two surgical techniques.

Methods: Two high-risk patients, first had a large median and one para median and the second had a median and in the left upper abdomen an incisional hernia. The median hernia was closed in both patients with a mesh according to the Erlangen-Inlay-Onlay Mesh Repair (EIOM) procedure. The lateral incisional hernias were closed with the so-called Extended Spider-Suture Technique (ESST). The patients were then followed up for two years.

Results: Both patients were very satisfied after two years and would recommend the operation to others. The clinical and sonographic examination of the two patients showed no evidence of hernia recurrence.

Conclusion: The combination of both surgical techniques EIOM and ESST showed that all types of abdominal wall hernias can be treated safely even in high-risk patients.

© 2020 Resit Demir. Hosting by Science Repository. All rights reserved.

Introduction

Incisional hernia after a laparotomy is an unsolved problem. 20% of all patients who are operated on using today's closure technique after laparotomy develop an incisional hernia [1]. It becomes even more complicated if the abdominal wall has several hernias which have arisen after several abdominal operations. There is no standard therapy in this situation. The surgeon must individually decide which technique to use for closing the hernia. In the following work, I would like to introduce two combined techniques that I have performed on two high risk patients for closing their incisional hernia.

Material and Methods

I Patient H.B.

i History

46-year-old, BMI 30 kg/m². Situation after splenectomy with a left subcostal incision due to spontaneous splenic rupture 04/2016. Situation after median laparotomy for diffuse bleeding 5/2016 with acute liver failure, kidney failure and haemorrhagic shock. Situation after drug abuse, nicotine abuse, situation after mechanical aortic valve replacement for aortic valve endocarditis 2012, coronary heart disease with high-grade occlusion of the coronary arteries, situation after by-pass (LIMA-RIVA) surgery on the heart 2012. Obesity, drug addiction, type II diabetes mellitus, hypertriglyceridemia, chronic obstructive

*Correspondence to: Priv.-Doz. Dr. med. Resit Demir, Medical Care Center, MVZ PD Dr. Demir & Colleagues Schweinauer Hauptstrasse 12, 90441 Nürnberg, Department of Surgery, University Hospital Erlangen, Maximiliansplatz 2, 91054 Erlangen, Germany; Tel: +49911966170; Fax: +499119661735; E-mail: demir@mvz-demir.de

pulmonary disease, hypothyroidism, allergy to amoxicillin, diclofenac. Oral anticoagulation with Marcumar.

ii Finding

Mr. B. had a complete, median, ventral incisional hernia from the xyphoid to the symphysis (28x15cm). An additional incisional hernia because of a left subcostal incision (10x6cm) (Figure 1). Mr. B. could not walk without a belly bandage because the intestines always prolapse outwards. After several clinics rejected the patient to operate because of the size of hernias and the risk of surgery, patient was presented to us. Patient's suffering was very high. After appropriate operational clarification and conversion of the blood thinning to heparin, patient was operated on April 19, 2017.

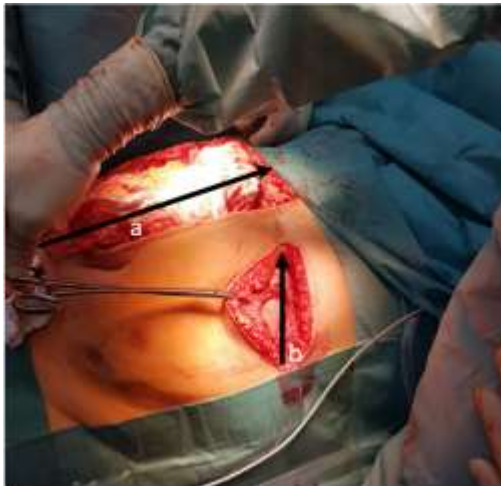

Figure 1: A) Mediane 28x15cm incisional Hernia. B) Left subcostal 10x6cm incisional Hernia.

iii Operation Method

Intraoperatively, there was a large median incisional hernia (28 x 15 cm) and a left subcostal hernia (10 x 6 cm) (Figure 1). After the intestines were moved back into the abdominal cavity, the fascia margins were prepared exactly 2cm.

a Subcostal Hernia: Closure with Extended Spider-Suture Technique

First, subcostal hernia on the left sight was operated. The Extended Spider-Suture Technique was used for this [2]. The seams used were made with Prolene 0 threads. An inner circular seam was placed 1 cm along the edges of the fascia (Figure 2A). The fascia edges were then closed using a continuous suture technique, starting from the medial and lateral sides. Care was taken to ensure that the stitches lie outside the inner circular seam. After knotting the inner circular seam, the continuous seam was knotted (Figure 2B). Finally, a second circular seam is made and knotted at a distance of 1 cm from the inner circular seam (Figure 2C). The wound is closed with subcutaneous Redon drainage, subcutaneous suturing, and skin suturing.

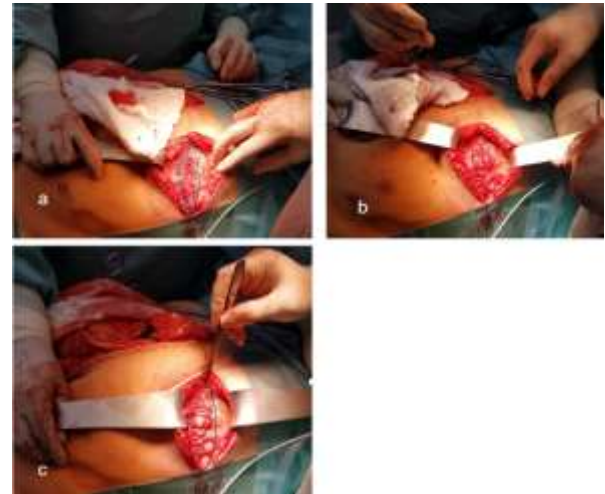


Figure 2: Extended Spider Suture: A) Inner circular suture 1cm along the fascia edge (blue dashed line). B) Continuous suture with puncture sites outside of the inner circular suture. C) Outer circular suture (black dashed line).

b Median Large Incisional Hernia: Erlangen Inlay-Onlay-Mesh Repair [3]

After the intestines have been moved back into the abdominal cavity, the hernia size was then measured. This was 28x15cm. Two Prolene meshes were adjusted (30x 11cm, fascia gap 5cm) and implanted into the abdominal wall using the Erlanger Inlay-Onlay-Mesh (EIOM) repair technique. 40 U-seam with double-armed 0-Prolene were used (Figure 3A) to fix the inlay mesh into the abdominal wall.

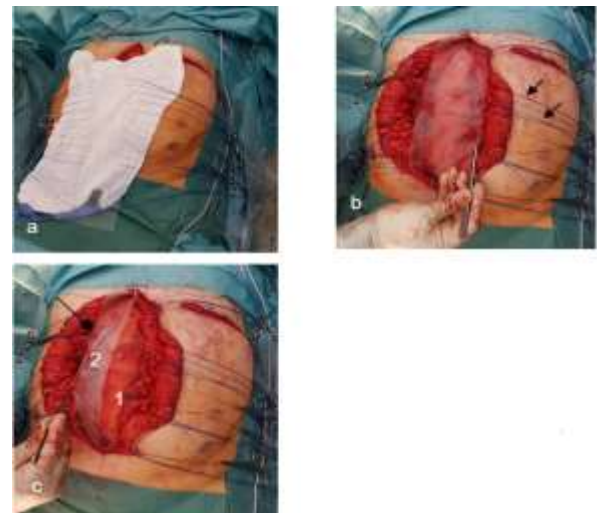


Figure 3: Erlanger Inlay-Onlay-Mesh Repair (EIOM). A) U-Seams were performed to the inlay mesh before threading the fascia. B) The inlay mesh is sewn. The U-seams were threaded from insight to out-sight of the fascia (▲). C) U-stiches performed before were now threaded through the second mesh and knotted (Figure 3C) (●) Mesh 1 and 2.

Then a second mesh were prepared for onlay position. U-stiches performed before were now threaded through the second mesh and knotted (Figures 3B & 3C). The fascia cannot be primarily anatomically reconstructed, because of the retraction of the abdominal musculature. There is a fascia gap of 5cm. Careful hemostasis. Wound closure via

Redon drainage, subcutaneous suturing, and skin suturing, sterile pressure dressing. Tummy bandage was put on.

II Patient A.K.

i History

65-year-old, BMI 33 Kg/m², an emergency right para median incision was first performed in 1993 with the suspicion of acute appendicitis. After persisting abdominal pain, median laparotomy was performed. Sigma diverticulitis was diagnosed at the operation and a sigmoid resection with a terminal colostomy in the left lower abdomen was performed via a median laparotomy. The colostomy was relocated after 6 months. After years patient developed an incisional hernia in the Para rectal incision and in the median incision of the fascia (Figures 4A & 4B).

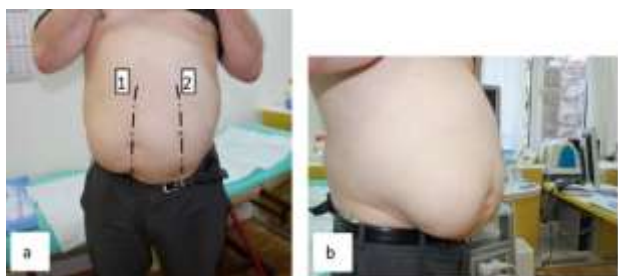

Figure 4: Patient developed incisional hernia after para median incision and median incision of the fascia **A)** anterior-posterior view, **B)** lateral view [1, 2].

Due to the secondary diagnoses and the bad experience in the former clinic, patient gave himself a lot of time (almost 27 years) until discomfort exceeded his fear. The patient decided to have surgery. After corresponding information about the highly operational risks, A.K. has given its approval for the operation.

ii Secondary Diagnoses

Coroner heart disease, heart attack with 3x stents was inserted, arterial hypertension, Type II diabetes mellitus, oral anticoagulation with Marcumar.

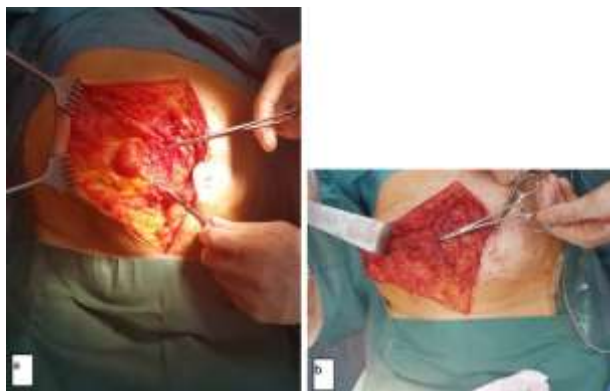

Figure 5: **A)** Para rectal incisional hernia: size 6x7cm. **B)** The hernia was treated according to Demir's extended spider suturing technique [2].

iii Operation Method

a Right Paramedian Hernia: Closure with Extended Spider-Suture Technique

Para median incisional hernia (6x7cm) was closed with the Extended Spider-Suture Technique (Figures 5A & 5B) [2]. An inner circular seam, a continuous seam and two outer circular seams were used. Prolene 0 (Ethicon) was used as the suture material.

b Median Large Incisional Hernia: Erlangen Inlay-Onlay-Mesh Repair [3]

The median hernia was 15x10cm (Figure 6A). Median hernia repair was according to EIOM with a mesh size of 19x7cm (Figure 6B).

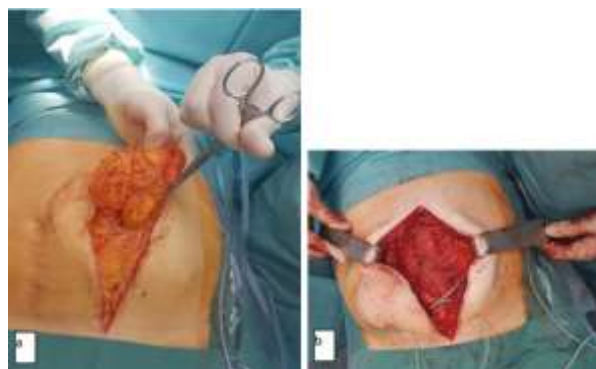


Figure 6: **A)** Median incisional hernia: size 15x10cm. **B)** The hernia was treated according to the Erlangen Inlay Onlay Mesh Repair (EIOM Technique). Mesh size was 19x7cm.

Results

I Patient H.B.

After a 5-day hospital stay, the patient could be discharged home. The postoperative course was initially uncomplicated. The drainage and the sutures could be removed in time. The patient was marcumarized again. About four weeks later, the patient slowly developed a subcutaneous seroma. On May 15th, 2017, a drainage Ch12 was performed under local anaesthesia. At the first go, 350 ml of bloody liquid was emptied. The drainage could be removed after 2 weeks because it no longer delivered. After a few weeks, the patient developed subcutaneous seroma again. This was then regularly punctured. In addition, due to the thinning of the blood, Marcumar was switched to heparin. The last puncture was performed on June 19, 2017. The further course of the operation was normal.

The clinical and sonographic examination in the follow-up on December 18, 2018, i.e. 20 months later, showed no evidence of recurrence. The patient was very satisfied with the operation and would recommend the operation to others. We received the last information on December 19, 2019 (32 months postoperatively) from his family doctor, after which we were unable to reach the patient. The family doctor told us that the patient would be very well belonging his incisional hernia. Patient had an advanced triple Coroner Arterial Disease, which could no longer be supplied with a stent. That is why an operation on the heart would be pending.

II Patient K.A.

The postoperative time lapse was uncomplicated. The wound healed by primam and the sutures and drainage could be removed in time. The patient still wore a tummy bandage 4 weeks postoperatively. In the follow-up, the patient was last examined on December 11, 2019, 24 months postoperatively. The patient stated that there were no complaints either at rest or during movement. The patient is very satisfied with the operation and would recommend the operation to others. The clinical and sonographic examination showed no evidence of recurrence.

Conclusion

Large and multiple hernias on one patient is a challenge for the surgeon to handle. Two surgical techniques were used in combination with each other on one patient in order to reduce foreign materials (meshes) as possible into the abdominal wall and to limit the collateral damage as little as possible. The para median hernia of the first patient and the subcostal left upper abdomen hernia of the second patient were operated using the Extended Spider-Suture Technique [2].

Extended Spider-Suture Technique is a kind of direct seam of the fascia, which was developed in-house. The aim of this technique is not only to close a abdominal wall continuously or with single button suturing, but also by applying circular sutures that run parallel to the edges of the fascia or, if necessary, using transverse sutures, such as a spider web, to reduce pressure to the closing seam in the middle. A simple circular seam showed on a paper test that the carrying capacity of the sutured paper raised on average from 1777g to 5102g. That meant an increase of 287 % [2]. This technique is used in our house for median abdominal wall hernias also. Depending on the quality of the fascia, a basic or an extended spider suturing technique is used. This technique has been carried out in our house since 2013. A prospective data analysis of the results of this surgical technique will follow. It would be useful to consider whether this suturing technique should also be used for primary abdominal wall closure in high-risk patients, e.g. BMI > 30, very poor fascia quality, after aortic aneurysm surgery.

The two median large abdominal wall hernias were operated on using the Erlangen Inlay-Onlay Mesh Repair Technique. All types of abdominal wall hernias can be operated on with this technique [3]. The biggest advantage of this technique is that there is no "large" preparation on the abdominal wall compared to other techniques, such as the sublay technique [4]. Because both patients were high risk patients.

Furthermore, a fascia gap can be left without achieving a primary anatomical fascia reconstruction. In this way, excessive intra-abdominal pressure can be avoided. In order to achieve a primary anatomical reconstruction, e.g. components separation according to Ramirez can be achieved [5]. However, this would mean major collateral damage, which would have incalculable consequences for these high-risk patients. For this reason, both patients were most likely rejected by other clinics. The freedom from complaint and the satisfaction of both patients gives hope that this type of surgical techniques for complicated abdominal wall hernias could be considered to be evaluated in a clinical study.

Disclosure

The authors reported no proprietary or commercial interest in any product mentioned or concept discussed in this article.

Conflicts of Interest

None.

Consent

The informed consent was obtained from patients.

REFERENCES

1. Burger JWA, Luijendijk RW, Hop WCJ, Halm JA, Verdaasdonk EGG et al. (2004) Long-term follow-up of a randomized controlled trial of suture versus mesh repair of incisional hernia. *Ann Surg* 240: 578-583. [[Crossref](#)]
2. Demir R (2018) Novel Suturing Technique for Fascia Closure after Laparotomy: Spider Suture to Increase the Tearing Force of the Fascia. *Int J Surg Res* 5: 107-110.
3. Ayik N, Klein P, Grutzmann R, Demir R (2019) Long-term Outcome of Incisional Hernia Repairs Using the Erlangen Inlay Onlay Mesh (EIOM) Technique. *J Surg Res* 243: 14-22. [[Crossref](#)]
4. Schumpelick V, Klinge U, Junge K, Stumpf M (2004) Incisional abdominal hernia: the open mesh repair. *Langenbecks Arch Surg* 389: 1-5. [[Crossref](#)]
5. Ramirez OM, Ruas E, Dellon AL (1990) "Components separation" method for closure of abdominal-wall defects: an anatomic and clinical study. *Plast Reconstr Surg* 86: 519-526. [[Crossref](#)]